

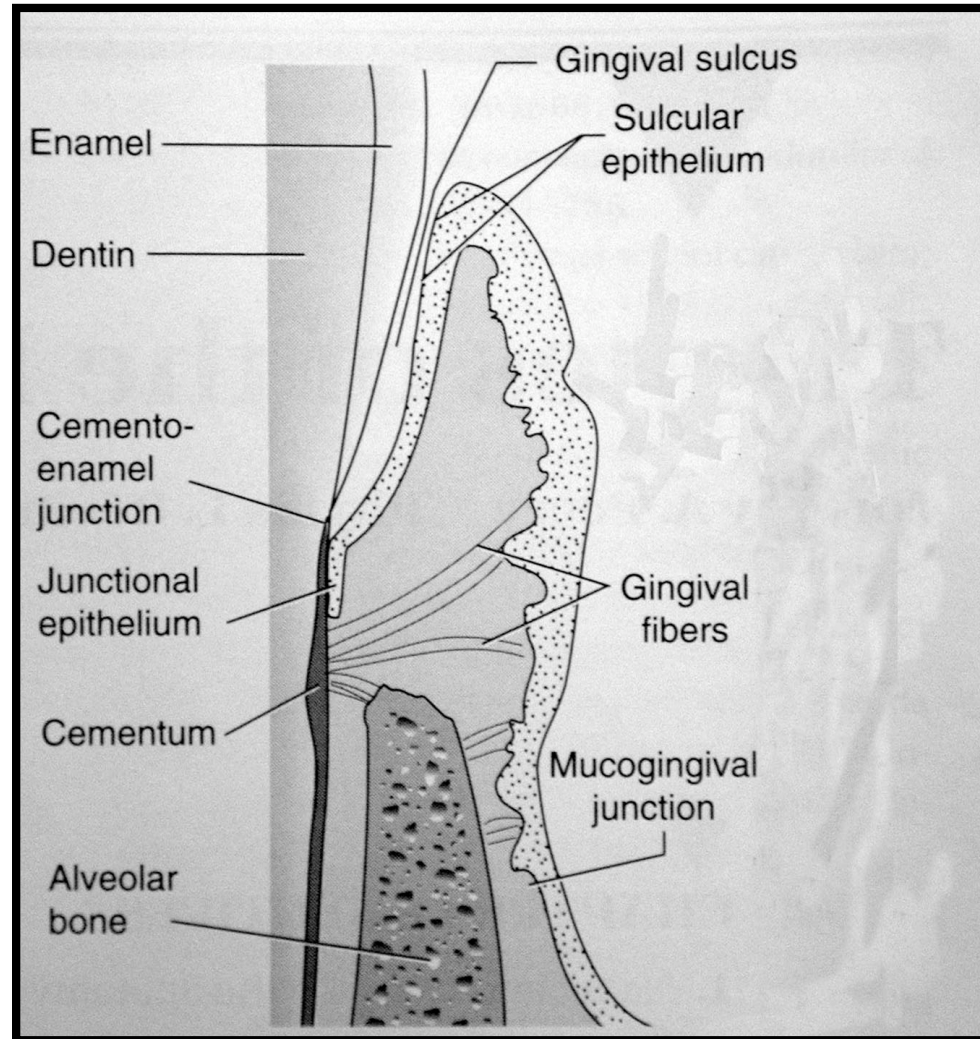
The Boston Line

The Basis of Perio

Biologic Width

(the bottom of the pocket)

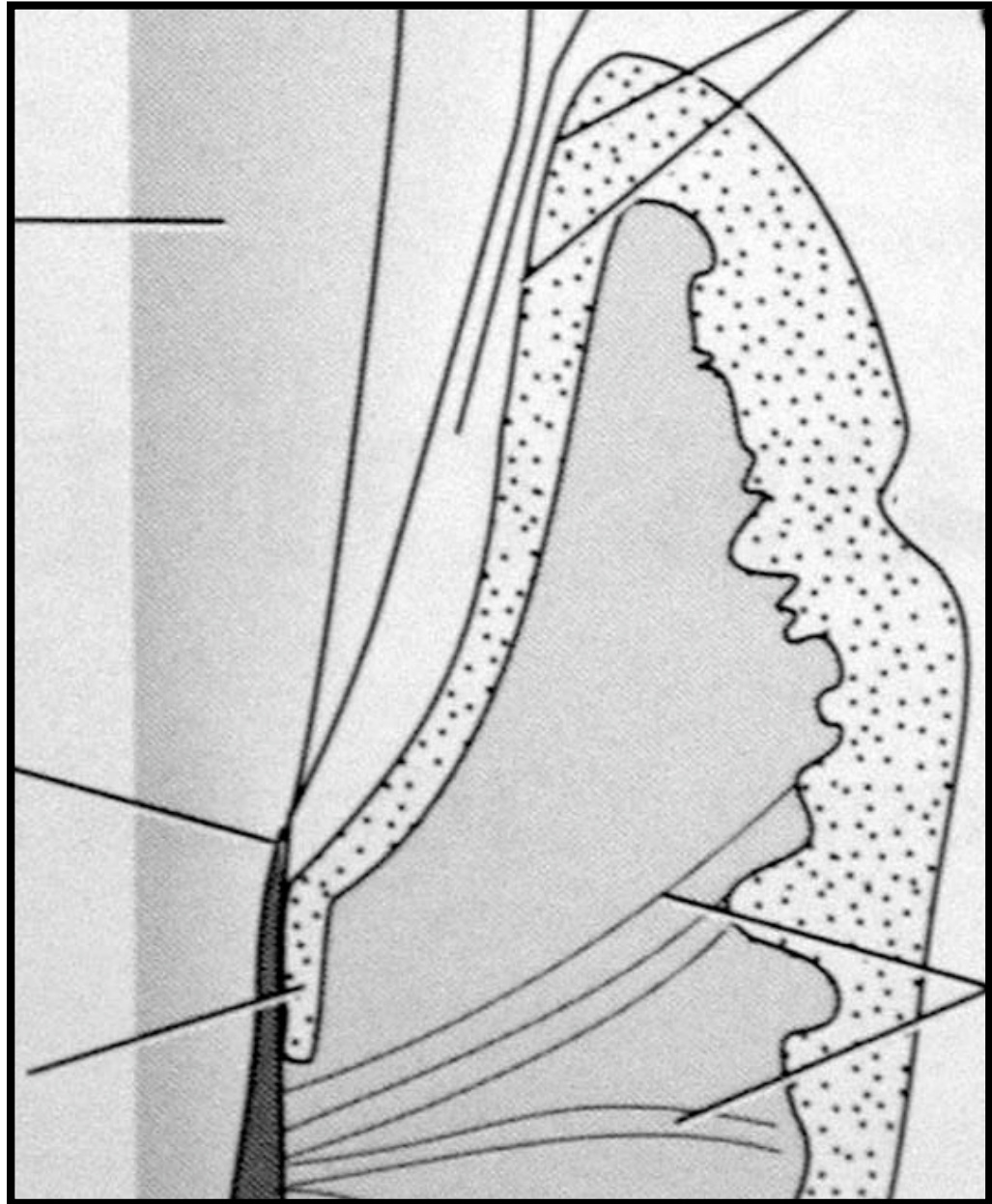
Biologic Width and Attachment Apparatus

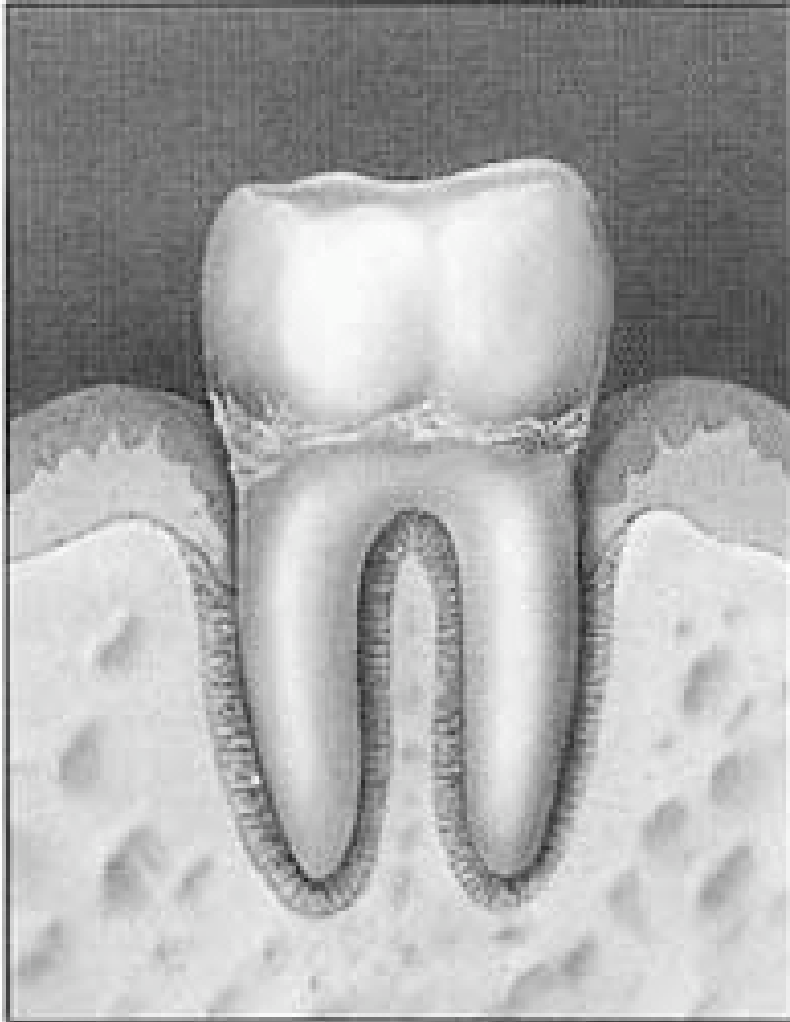


What is the disease status of this case?

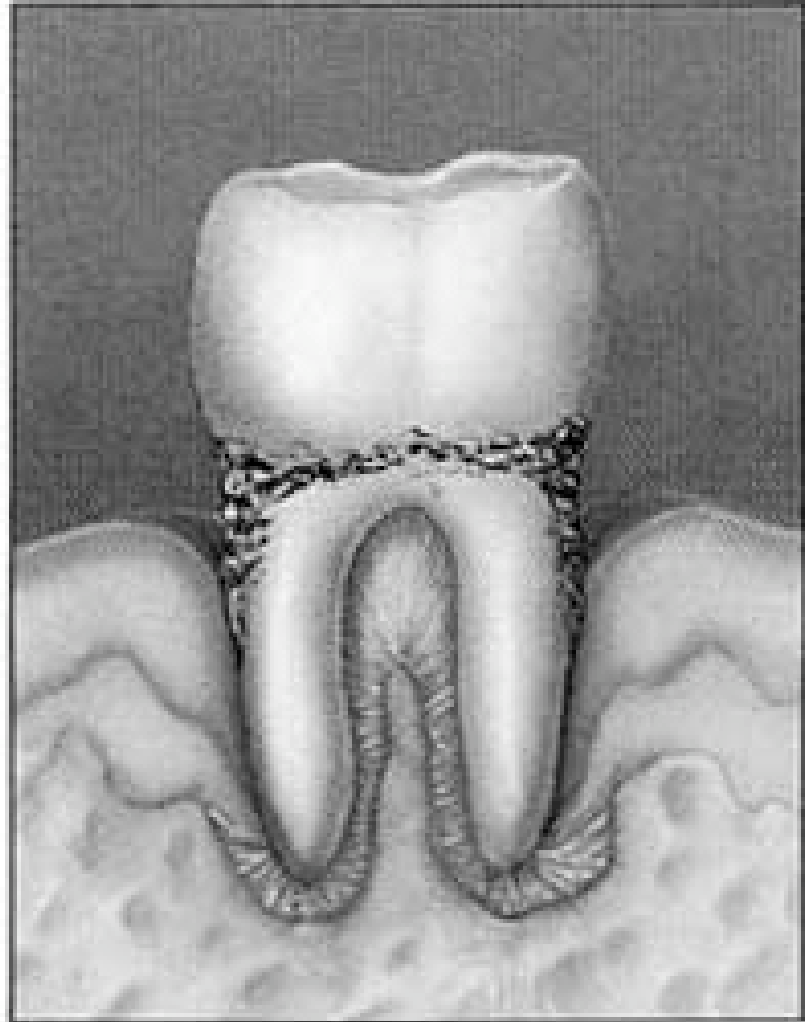
- A. Gingivitis**
- B. Periodontitis**
- C. Periodontal Abscess**
- D. Occlusal Trauma**
- E. None of the above**

Periodontitis





Gingivitis



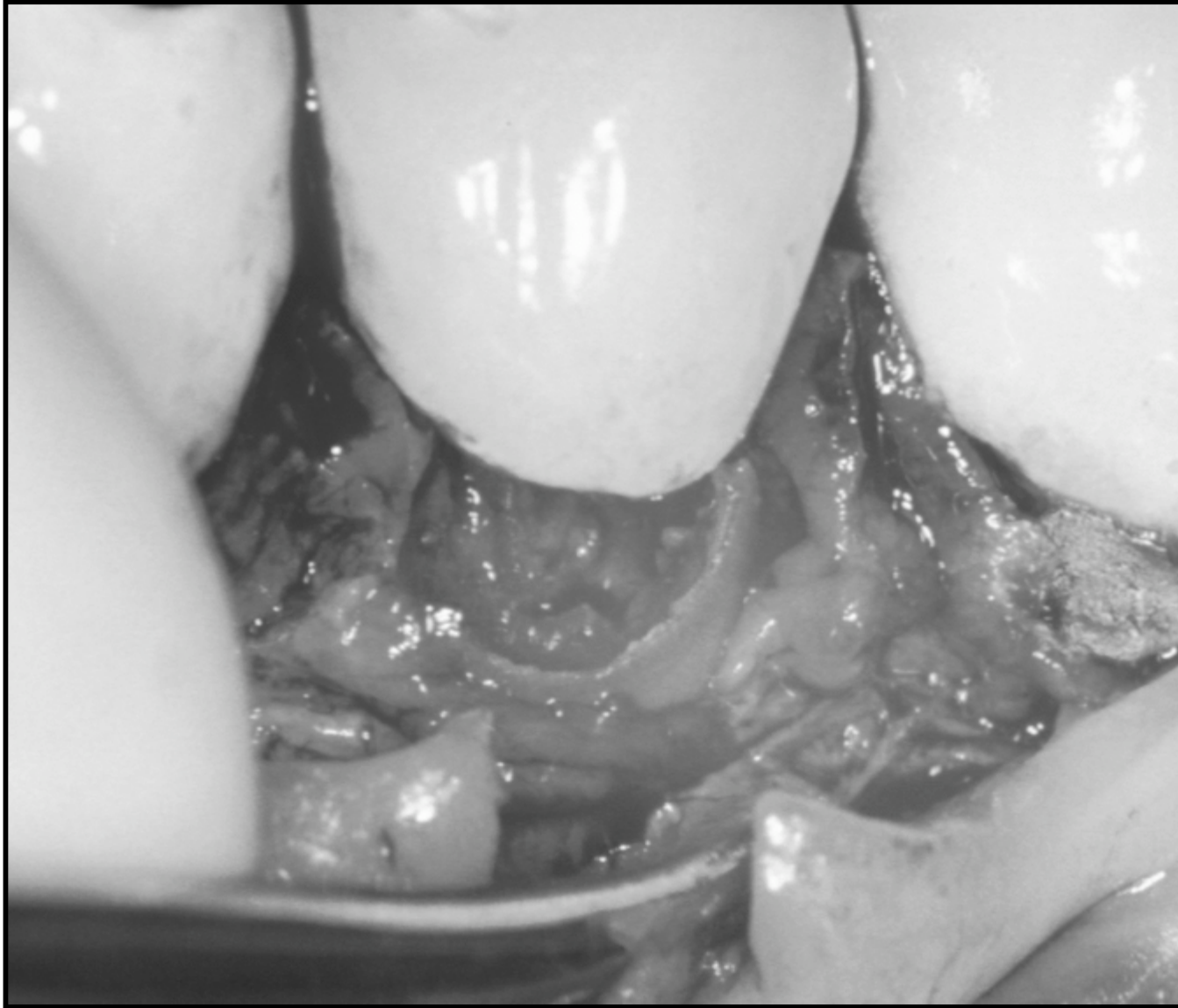
Severe Periodontitis

Biologic Width

- **Sulcus depth = 1-1.5 mm**
- **Junctional epithelium = 1 mm**
- **Connective tissue attachment= 1.07 mm**
- **Range of total attachment = 1.07 to 2.43 mm**

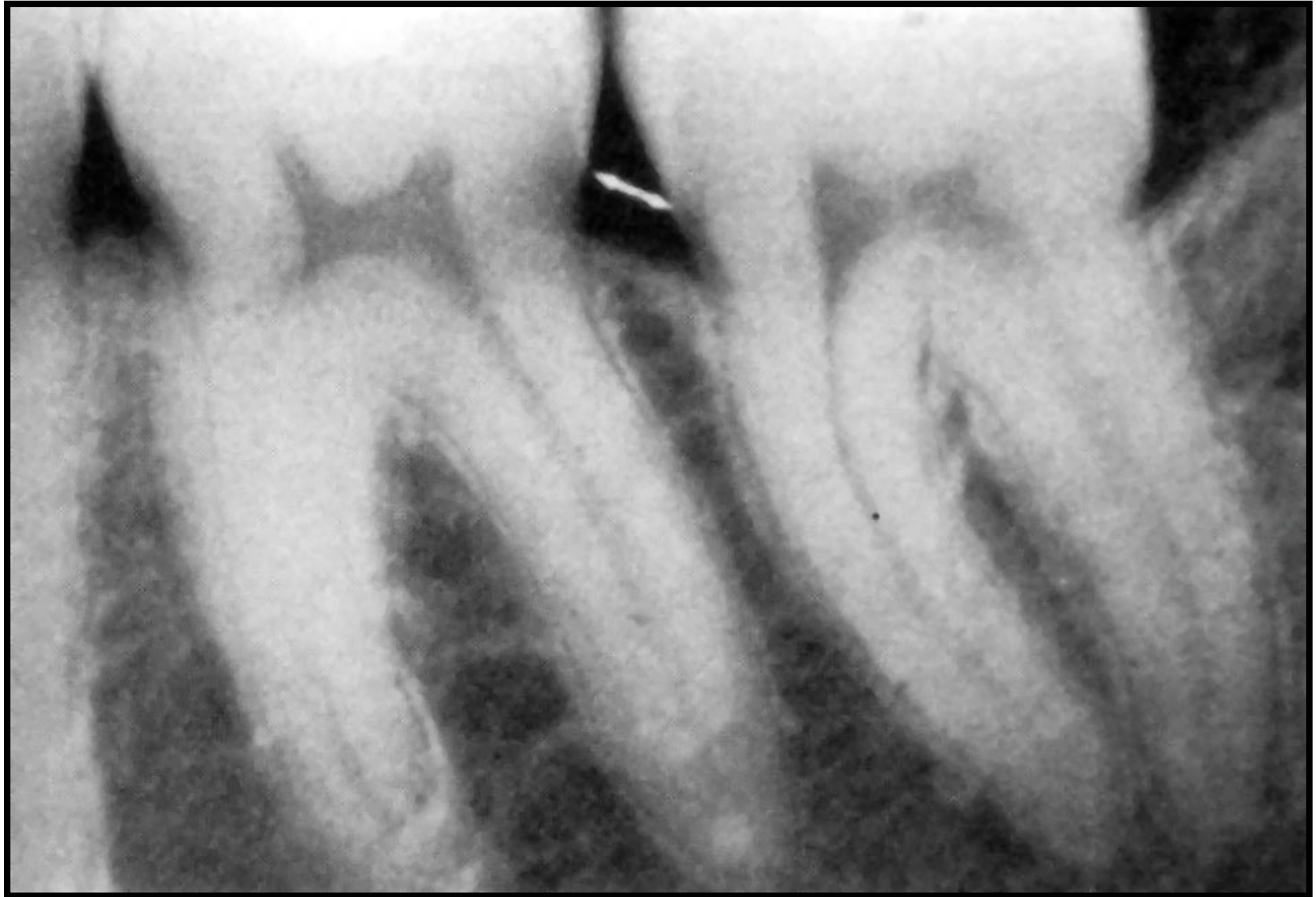**Distance from a proposed
restorative margin to the
alveolar crest should be
3 mm**

Violation of Biologic Width - Caries



**What is the normal
interproximal bone
height?**

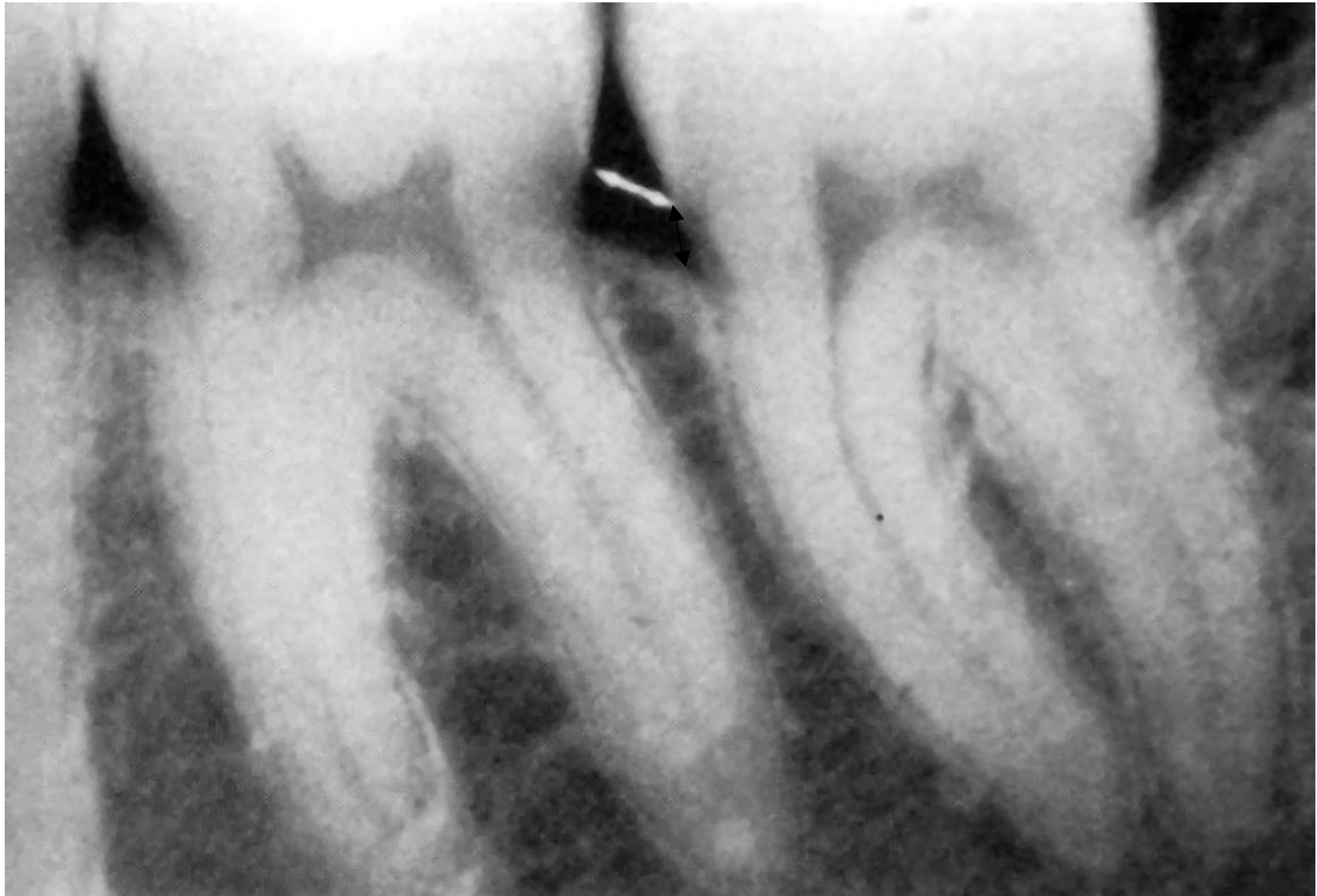Identification of the CEJ



AHC

JYS

Distance to the CEJ



AHC

JYS